

# Correlation between Functional MRI And Voice Improvement Following Type I Thyroplasty in Unilateral Vocal Fold Paralysis—A Case Study

\*,<sup>‡</sup>,<sup>†</sup>Jessica F. Galgano, <sup>†</sup>,<sup>§</sup>Kyung K. Peck, <sup>‡</sup>Ryan C. Branski, <sup>‡</sup>Dmitry Bogomolny, <sup>‡</sup>David Mener, <sup>‡</sup>Margaret Ho, <sup>†</sup>Andrei I. Holodny, and <sup>‡</sup>Dennis H. Kraus, *New York, New York*

**Summary:** The objectives of this study are to describe central nervous system modulation associated with voice improvement following Type I thyroplasty in a patient with glottic insufficiency secondary to unilateral vocal fold paralysis. Serial functional magnetic resonance imaging scans were performed before as well as one and six months after thyroplasty. Paradigms consisting of four voice production tasks and a motor control task were completed. Volumes of activation within regions activated during each task were measured. Acoustic and aerodynamic measures were also obtained. A widespread network of neural activations was shown for all tasks. Differences in volumes of activation 1-month postsurgery positively correlated with acoustic and aerodynamic improvements. Sixth months following medialization, lesser volumes of activation were observed in all regions. Prior to this session, however, the patient's mediastinal disease progressed, leading to a significant deterioration in voice. Functional differences between patient brain maps yield new information about the central nervous system's ability to reorganize sensorimotor representations associated with voice improvement following Type I thyroplasty in a patient with glottic insufficiency secondary to unilateral vocal fold paralysis (UVFP).

**Key Words:** fMRI—Cortical adaptation/modulation—Sensorimotor reorganization—Unilateral vocal fold paralysis—Thyroplasty.

## INTRODUCTION

The central mechanisms governing phonation in voice-disordered populations remain insufficiently characterized.<sup>1,2</sup> Further investigation is warranted to develop a more complete understanding of the neural correlates of voice disorders, and the ability of the central nervous system (CNS) to modulate activity before and after rehabilitation. Type I thyroplasty, a commonly used surgical rehabilitation approach for patients with voice disorder and glottic insufficiency due to unilateral vocal fold paralysis (UVFP), is associated with improved voice and swallowing.<sup>3–7</sup> Patients undergoing this type of surgical procedure provide an opportunity to examine a central mechanism of adaptation associated with dysphonia and its remediation following surgery.

Brain-imaging techniques such as functional Magnetic Resonance Imaging (fMRI) provide unique methods of measuring treatment effects and have been used to delineate differences in cortical and subcortical activity in a variety of patient populations.<sup>8–10</sup> Reports of central reorganization in patients with neurogenic voice disorders before and after behavioral and medicinal therapies have provided voice professionals with information regarding the impact voice disorders have on the CNS and treatment outcomes at the level of the CNS.<sup>2,11,12</sup>

For example, functional imaging investigations of phonation in patients with spasmodic dysphonia and hypophonia secondary to Parkinson's disease have identified many differences in neural activity, including reduced activations in primary sensorimotor, premotor, and sensory association regions. Studies have also examined the effects of various intervention approaches on voice disorders. For example, cortical reorganization associated with voice improvement following the Lee Silverman Voice Treatment program, structured voice therapy for speech and voice disorders, has been described.<sup>2</sup> Data suggest that the use of this rehabilitation approach to improve voice may result in a treatment-dependent functional reorganization, as evidenced by cortical activations that correlate with more efficient speech/voice motor actions and outcomes.<sup>2</sup> The effects of these interventions are associated with CNS changes; however, the underlying nature of these neural mechanisms is unknown.

A limited number of studies have examined the impact of dysphonia due to glottic insufficiency on CNS function. The current study attempted to address this gap by investigating subcortical and cortical activations before and after medialization laryngoplasty in a single subject with glottic insufficiency secondary to UVFP. The objectives of this study were to determine whether glottic insufficiency secondary to UVFP is associated with a differential pattern of neural activation and (2) voice improvement following Type I thyroplasty results in changes in the brain regions involved during phonation, as well as differences in the degrees of activation within activated regions.

## METHODS

### Subject

All procedures were approved by the Institutional Review Board at Memorial Sloan-Kettering Cancer Center. One 51-year-old female with glottic insufficiency due to UVFP

Accepted for publication January 31, 2008.

The work described in the current manuscript was supported by the generosity of the Langeloth Foundation, The Garban Fund, and Hackers for Hope. This work was presented at the American Laryngological Association Meeting, San Diego, California, May 2007.

From the \*Department of Speech-Language Pathology, Teacher's College, Columbia University, New York, NY, USA; †Department of Radiology, Memorial Sloan-Kettering Cancer Center, New York, NY, USA; ‡Department of Head and Neck Surgery, Memorial Sloan-Kettering Cancer Center, New York, NY, USA; and the §Department of Medical Physics, Memorial Sloan-Kettering Cancer Center, New York, NY, USA.

Address correspondence and reprint requests to Jessica Galgano. E-mail: jfg2102@columbia.edu (J.F.G.), or jessgalgano@yahoo.com

Journal of Voice, Vol. 23, No. 5, pp. 639–645

0892-1997/\$36.00

© 2009 The Voice Foundation

doi:10.1016/j.jvoice.2008.01.016

secondary to breast cancer metastasizing to the mediastinum and aorticopulmonary window participated in the study. Symptomatically, the patient was 3 months from the onset of paralysis. The surgeon's experience in patients with cranial neuropathy secondary to malignancy suggested complete denervation; however, electromyographic results to confirm this assertion were not obtained. The patient underwent an uneventful Type I Gortex<sup>®</sup> medialization due to complete vocal fold immobility. Acoustic, aerodynamic, and laryngoscopic evaluations, in addition to fMRI scans, were completed prior to surgical rehabilitation, 1 month following surgery (post 1), and 6 months following surgery (post 2). Prior to her 6-month follow-up fMRI session, the patient presented with a deterioration of voice. This was likely associated with the systemic effect of both the disease and chemotherapy received. In addition, the patient suffered from progressive cancer cachexia and peripheral weight loss, associated with declining pulmonary function and breath support/control for voice production. Voice deterioration was not a function of tumor infiltration or mass effect.

### fMRI paradigms

Voice generation tasks were performed briefly once every 16 seconds to reduce motion-related artifact.<sup>13</sup> Tasks were randomly ordered at each scan. The patient participated in a training phase, which served to educate the patient on the expected responses.

Items consisted of four voice production tasks and a motor control task (i.e., finger tapping). Specifically, the patient generated 10 trials of the "uh" sound for a maximum duration of 4 seconds followed by 16 seconds of rest. The "uh" task was performed at three pitches: high, comfortable, and low. The patient was also instructed to repeat "uh" over 4 seconds. Finger tapping was performed as a neurological control. It served as a reference between scans and is a robust signal that is less variable than voice generation tasks. It also supports the comparison between pre and post fMRI scans and to confirm scanner stability for the longitudinal study of the patient. Prior to fMRI scanning, these functional paradigms were practiced outside of the scanner until the patient could execute the task successfully.

The functional tasks used in the current study were developed to avoid methodological confounds between voice, speech, and language tasks. Requiring the patient to produce linguistically complex units, such as sounds or words<sup>14-16</sup> leads to some debate concerning whether brain activations for speech or language are lateralized to the dominant hemisphere for language. In addition, the current study sought to avoid movement artifacts involved in speech and speech-like movements such as lip pursing or vowel production, in particular the back, tense, rounded vowels (such as /u/), or sounds which require extensive mandibular excursion (such as /a/) and by using a task which requires a neutral lingual position, involves voicing *only*, and has no related speech or language overlay.

### fMRI experimental procedures

fMRI data were acquired with a 3 T GE Signa LX Scanner (GE Medical System, Milwaukee, WI) with a standard birdcage

head coil. Twenty-six contiguous slices parallel to the anterior-posterior commissure (AC-PC line) and covering the whole brain were acquired using a gradient echo echo-planar imaging sequence with the following parameters: 2,000-millisecond (TR); 30-millisecond (TE); 90°-flip angle; 240-mm (FOV); 4.5-mm slice thickness; 128 × 128 matrix. An additional eight excitations without image collection (16 seconds) prefaced the initiation of the functional imaging run to allow the MR signal to reach equilibrium. Anatomical images were obtained using T1-weighted spin-echo images (400-millisecond TR; 14-millisecond TE; 90°-flip angle; 256 × 256 matrix; 4.5-mm thickness; 26 slices; 240-mm FOV) and a T1-weighted three-dimensional-spoiled GRASS sequence (6.9-millisecond TR; 3-millisecond TE; 15°-flip angle; 256 × 256 matrix; 1.5-mm thickness; 124 slices; 240-mm FOV). The functional echo-planar imaging and anatomic T1-weighted spin-echo images were acquired with the same number of sections and orientations for anatomical co-registration of observed activations.

E-Prime (Psychology Software Tools, Pittsburgh, PA) was used to control and present experimental stimuli to the subject, control scanner initialization sequences, and coordinate timing of stimulus presentation with scanner operations. The subject was instructed to perform the tasks, which were displayed on screens that were visible with specially made glasses. This was followed by a fixation point for a time interval of 16 seconds. The cycle then repeated for a total of 10 trials.

### Image processing and data analysis

Image processing and statistical analysis were performed with analysis of functional neuro images software.<sup>17</sup> The reconstructed fMRI data were aligned using a three-dimensional rigid-body registration method. Spatial smoothing using a Gaussian filter of 4 mm and temporal filtering to reduce high frequency noise were applied. Analysis of functional neuro images' deconvolution analysis was applied to estimate the impulse response function of the fMRI signal on a voxel-wise basis. Estimate of the impulse response function began at the onset of the voice generation, and the impulse response function was estimated to 16 seconds (eight images). This analysis produced an estimated hemodynamic response relative to the baseline state without making any assumptions regarding the shape, delay, or magnitude of the impulse response function. The estimated hemodynamic response was subsequently convolved with the temporal sequence of voice generation blocks. Goodness of fit of multiple linear regressions with the original time series was measured using the coefficient of determination. The significance of activation was assessed through the calculation of the *F*-statistic for regression. The coefficient of determination,  $R^2$ , was also calculated and was set to  $R^2 > 0.3$  ( $F > 6$ ).

The inherent difference in the time scales of blood oxygenation-level dependent hemodynamic response and voice induced signal changes was used to minimize voice-correlated motion artifacts by discarding the first few images after voice production and was incorporated with the deconvolution analysis. Additionally, to reduce false positive activity due to large venous structures or other artifacts, voxels were set to zero where the

standard deviation of the acquired time series exceeded 8% of the mean signal intensity. Anatomical and functional images were converted to standard Talairach atlas space with  $1\text{ mm}^3$  voxels. The volume of activation in the activated regions obtained from the patient study were measured in  $\text{mm}^3$  and compared between pre and two post scans.

The volume of activation was calculated using the number of pixels in the whole brain that passed a threshold of  $R^2$  value of 0.5. Figure 1 shows the  $R^2$  used to contrast the patient's production of comfortable pitch during both (A) pre and (B, C) post fMRI scans.

### Vocal function evaluation

Evaluation of vocal function served as a secondary endpoint for comparison with the neurological correlates of voice production. A certified speech–language pathologist conducted all voice assessments. Vocal function was assessed acoustically, aerodynamically, and stroboscopically. The patient was seated comfortably in a quiet room. The acoustic signal was obtained with a head-mounted telex unidirectional microphone and digitized, stored, and analyzed using a Kay Elemetrics model 4300B Computerized Speech Lab System. Airflow and air pressure data were obtained with a Fleisch pneumotacograph and intraoral pressure probe, and digitalized, stored, and analyzed using an F–J Aerophone II system. The laryngeal video stroboscopic examination was performed with a Kay Elemetrics model RLS 9100 computer-interfaced unit.

Average fundamental frequency was obtained during an all-voice phrase.<sup>18</sup> Noise to harmonic ratio was assessed during continuous voicing at a comfortable pitch and loudness using the (MDVP) voice analysis program (KayPentax, Lincoln Park, New Jersey). Mean phonatory airflow and estimated driving pressure data were collected during productions of “pi” at a comfortable pitch and loudness<sup>19</sup> via Aerophone (KayPentax, Lincoln Park).

## RESULTS

Significantly different volumes of activation in a widespread network of regions (Table 1; Figure 2) were observed one

month after surgery for all voice tasks. Three-dimensional render images (in the Talairach-Tournoux standard space) showing a standard view of all of cortical and subcortical regions active in the patient have been included as a reference (Figure 3). These findings correlate with improved acoustic and aerodynamic measures (Figure 4). Six months following surgery, significantly reduced volumes of activation were evident in all regions (Table 1). This coincided with deterioration of the patient's voice and overall health.

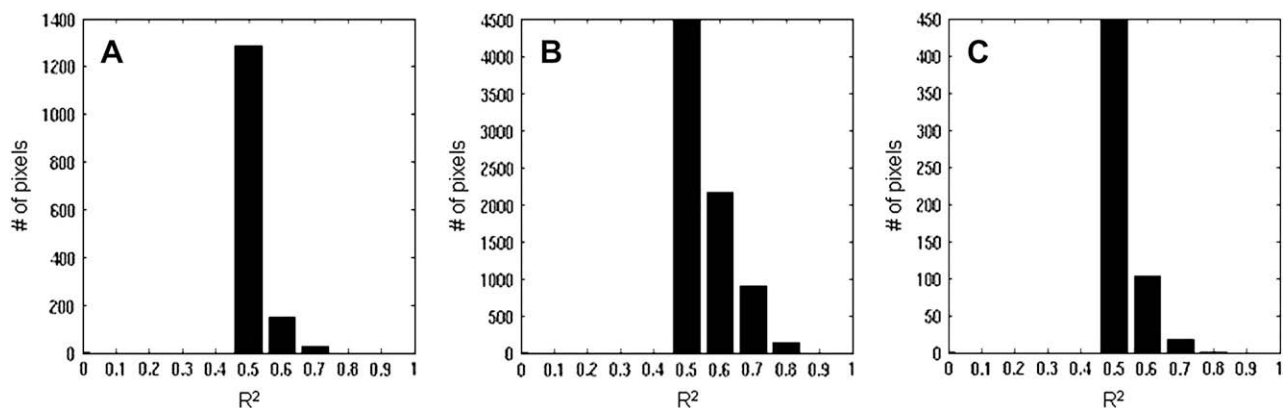
### Common activations across all tasks

Four regions were commonly exhibited across all voice production tasks before and after surgery. Bilateral activations included the precentral gyri continuing to the inferior frontal gyri rostrally, and to the superior temporal gyri inferiorly. Bilateral cerebellar activation was also evident across all tasks (Table 1; Figure 2).

**Comparison between comfortable pitch versus rest (passive respiration).** Several regions were active during comfortable pitch production. Activations in the frontal lobe included premotor planning areas (i.e., right middle frontal gyrus) and primary motor areas (i.e., precentral gyri) as well as the left inferior frontal gyrus (Figure 2). In addition, the superior temporal gyrus, left inferior and superior parietal lobes, and cerebellum were involved in modal pitch production (Table 1; Figure 2).

**Comparisons between high/low/repeat pitch productions versus rest.** Tasks requiring increased vocal efficiency, including high and low-pitch production, recruited the right middle frontal gyrus, precentral gyri, and inferior frontal gyri (Figure 2). Additionally, the superior temporal gyri, bilateral inferior and superior parietal lobes, left thalamus, and cerebellum were involved in high and low-pitch productions as well as repeated vocalizations in modal pitch (Table 1; Figure 2).

**Finger tapping versus rest.** Areas of activation in the patient during the finger-tapping task yielded information to support the comparison between pre and post-surgical scans. Blood oxygenation-level dependent percent signal change in the



**FIGURE 1.**  $R^2$  distribution histograms are shown here. The number of pixels in the segmented brain that pass an  $R^2$  threshold value of 0.5 were counted. Data obtained from the patient's production of a comfortable pitch compares (A) pre, (B) post 1, and (C) post 2 scans. Increased activations in the scan 1-month postsurgery scan and decreased activations in the scan 6 months postsurgery are shown.

**TABLE 1.**  
**Comparison of volume of activation (VOA) between pre- and post-fMRI scans in patients**

		CO			HI			LO			RE		
		Pre	Post 1	Post 2	Pre	Post 1	Post 2	Pre	Post 1	Post 2	Pre	Post 1	Post 2
Precentral Gyrus	R	1680	4318	440	10456	8243	754	1963	1554	926	4035	6343	628
	L	1758	4239	173	11759	8886	1099	1900	2339	958	5291	7018	565
Superior Temporal Gyrus	R		4255			5997	408	942			236	1382	126
	L	926	3611	440	1617	3313	848	816	487		1492	1523	236
Inferior Frontal Gyrus	R	361			2481	2324		644				958	
	L		298		2324	3266		424	110		911	801	
Inferior Parietal Lobe	R												
	L	345	2324			1806			236	251		518	565
Middle Frontal Gyrus			180		2591	4270	502	816		408	581		141
Superior Parietal Lobe	R					188							
	L		1680			518					251		
Thalamus	R												
	L					251							
Cerebellum	R	973	1460		3203	1570		1444	911	989	550	769	
	L	1256	1492	251	3171	942	895	816	2340	722	722	738	94

VOA (mm) was measured using  $1.87 \times 1.87$  (inplane resolution)  $\times 4.5$  (thickness) number of pixels. Areas showing greater volumes of activation after surgery are highlighted in yellow. Those showing increased volumes of activation before surgery are highlighted in blue (Post-1: one-month post-thyroplasty; Post-2: six-months post-thyroplasty; CO, comfortable pitch; HI, high pitch; LO, low pitch; RE, repeat; R, right hemisphere; L, left hemisphere).

primary motor cortex (M1) was stable (2–2.5%) between scanning sessions.

### Clinical data and voice analyses

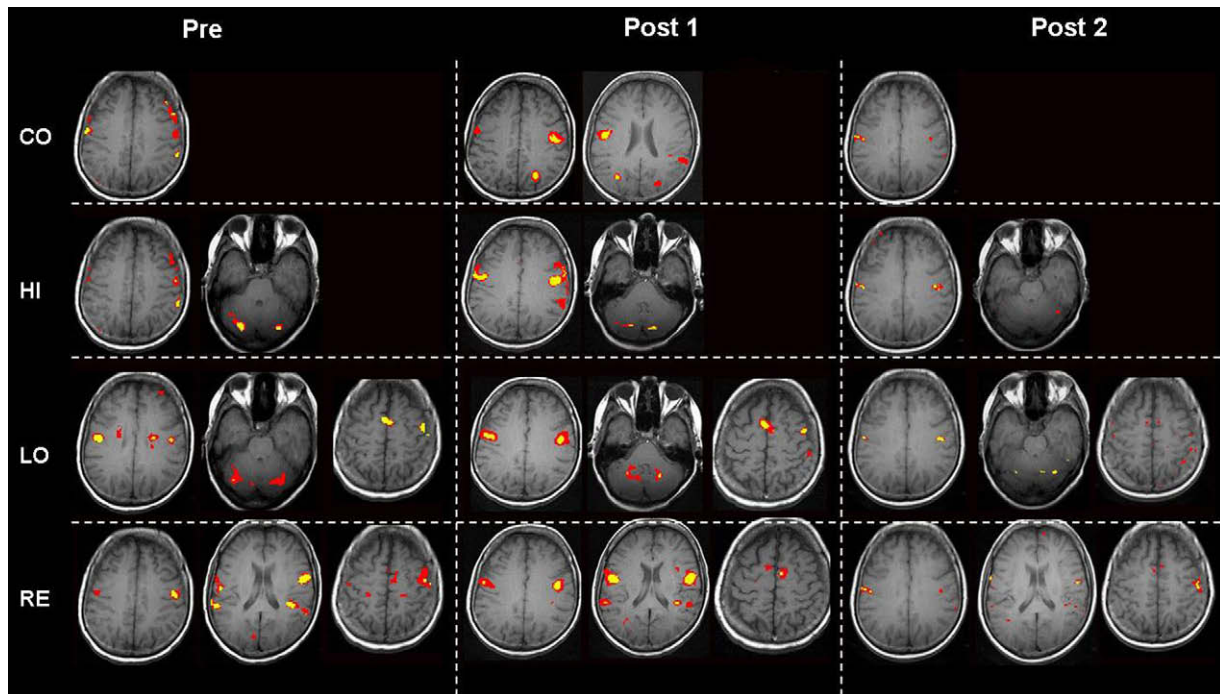
Analysis of the patient's recordings revealed improvements across all acoustic and aerodynamic parameters (Figure 4) one month following surgery (Figure 5). Six months after surgery, acoustic and aerodynamic measures declined. This reflected the patient's voice decline, likely associated with disease progression.

### DISCUSSION

Thyroplasty has been shown to be an effective means to ameliorate symptoms of voice disorder associated with glottic insufficiency and vocal fold paralysis.<sup>6,7</sup> Reported findings are consistent with the results obtained from the patient examined in the present study. fMRI results are likely associated with improved voice production due to restored glottic efficiency.

These findings provide evidence to support the suggestion that voice improvements obtained after surgery affect the CNS. The current study sought to describe changes in the locations and degrees of subcortical and cortical activations before and after Type I thyroplasty for glottic insufficiency and UVFP in one patient. Results of this case study exhibit a widespread network of neural activations associated with improved voice production following surgery. Functional differences between patient brain maps showing changes in sensorimotor representations before and after thyroplasty yield new information about the CNS's ability to modulate neural activity. This may reflect the ability of the cortex to reorganize activity in the areas involved in the planning, execution, and control of the structures and subsystems necessary for voice production.

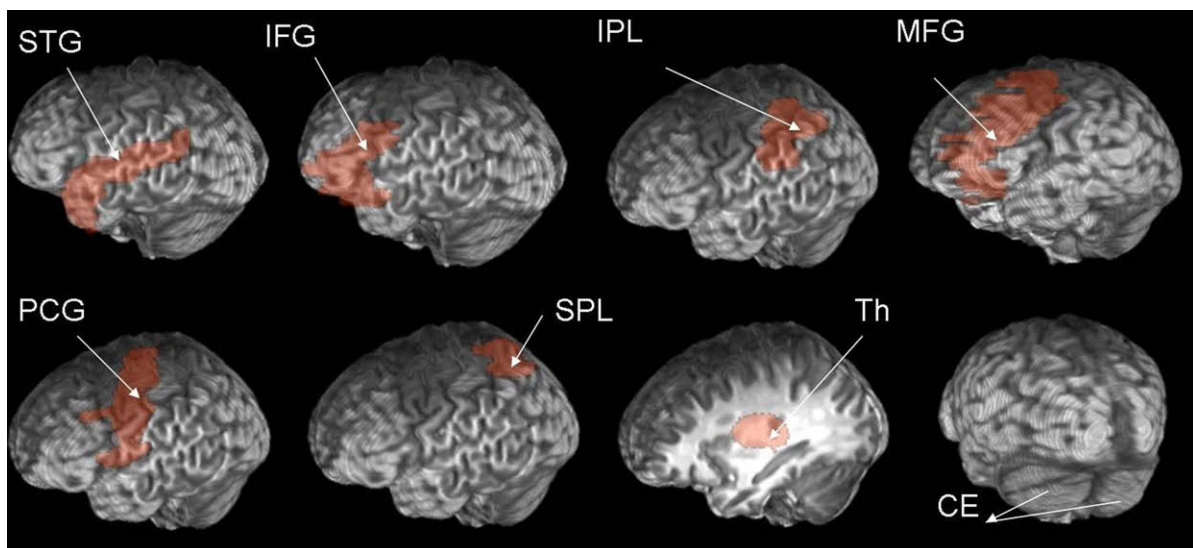
Clinical improvements in voice function shown 1 month following thyroplasty positively correlated with changes in neural activations. These results suggest that CNS changes reflect an increasingly efficient way of producing voice, possibly due to the ability of the CNS to process new sensory information



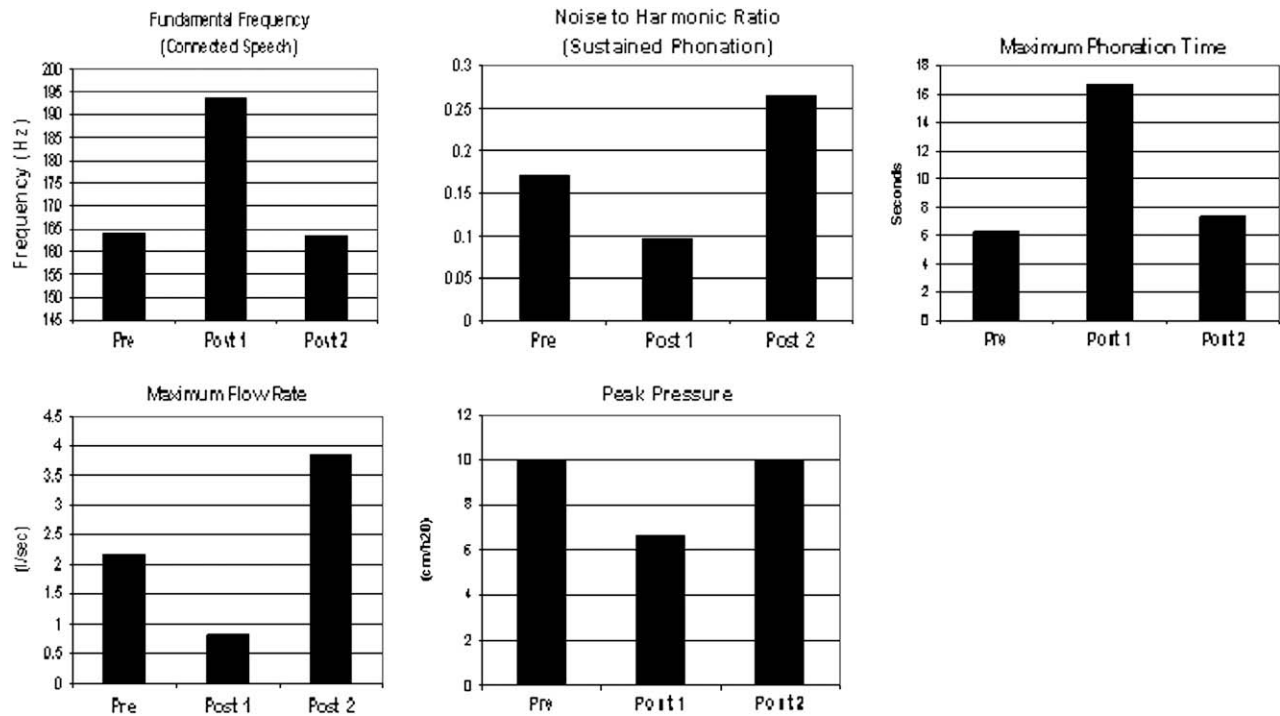
**FIGURE 2.** Network of activations was shown in the patient. Areas of activation during voice production at comfortable pitch (CO), high pitch (HI), low pitch (LO), and repeated vocalization (at comfortable pitch (RE)) are displayed. Scans are statistical parametric maps that show brain activations presurgery (left), 1-month postsurgery (center), and 6 months postsurgery (right). Red blobs indicate  $P < 0.005$  corrected,  $R^2 > 0.3$ ; yellow blobs indicate  $P < 0.001$ ,  $R^2 > 0.4$ . Regions of activation displayed in this figure include: (A) comfortable pitch: precentral gyrus and inferior parietal lobe, (B) high pitch: precentral gyrus, inferior parietal lobe, and cerebellum, (C) low pitch: precentral gyrus, cerebellum, and supplementary motor area, and (D) repetition of sound: precentral gyrus, superior temporal gyrus, and supplementary motor area.

accessible with regained function after surgery. These results also may support the notion that rehabilitation (in this case, surgery) acts as a tool to recalibrate the cortical structures necessary for functional voice production.

Acoustic and aerodynamic measurements associated with voice improvements following surgery positively correlated with changes in activations in frontal, temporal, and parietal cortices, and the cerebellum during all tasks. After surgery,



**FIGURE 3.** Displayed are three-dimensional render images (in the Talairach-Tournoux standard space) showing a standard view of all of the cortical and subcortical regions that were active in the patient. Only regions in the left hemisphere are shown. Abbreviations: (top row from left to right) STG: superior temporal gyrus; IFG: inferior frontal gyrus; IPL: inferior parietal lobe; MFG: middle frontal gyrus; (bottom row from left to right) PCG: precentral gyrus; SPL: superior parietal lobe; Th: thalamus; CE: cerebellum. For brain maps specific to the patient, please refer to Figure 2.

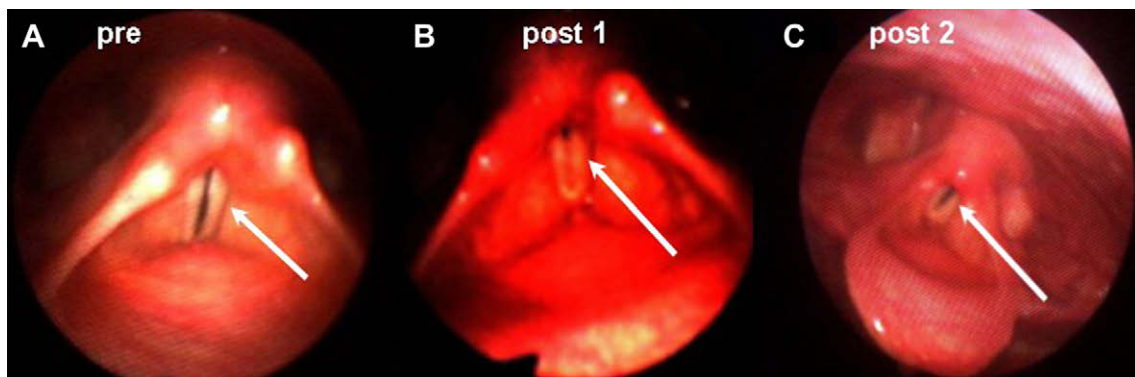


**FIGURE 4.** Quantitative voice parameters were obtained during voice evaluations. Assessments were conducted before (pre), 1-month postsurgery (post 1), and 6 months after surgical rehabilitation (post 2). One month following surgery (post 1), acoustic and aerodynamic measures returned to the normal limit range for the patient's age and gender. Six months following surgery (post 2), acoustic and aerodynamic measures were found to be outside the normal limit range due to the presence of a new voice disorder secondary to disease progression and initiation of systemic treatment.

greater volumes of activation associated with voice improvement were noted, in part, in premotor planning (middle frontal gyri) and motor execution areas (precentral gyri) in the frontal lobe across all tasks. Increased degrees of activation were also shown in the cerebellum. The cerebellum is known to have projections to motor regions in the frontal lobe, creating a cerebellar feedback loop for muscle movements. Activation in frontal pre- and primary motor regions and in the cerebellum may demonstrate the brain's skill in adapting to changes in motor performance, in this case, more efficient voice production, by improving its ability to correct motor output errors.<sup>20</sup>

Central monitoring and modulation of activity associated with vocal efficiency obtained after surgery was also evidenced by greater volumes of activation in the thalamus and inferior and superior parietal lobes. The inferior and superior parietal lobes are associational cortices involved in multimodal sensory integration and perceptual calibration. These processes are seemingly crucial for efficient voice production<sup>21,22</sup> because of the roles they play in somatosensory processes, association of multimodal sensory information, and motor regulation.<sup>23-25</sup>

Increased volumes of activation were also shown in the superior temporal gyrus, which may index a more efficient way of



**FIGURE 5.** Laryngoscopic examination results are shown at the time of the (A) presurgical examination (incomplete glottic closure), (B) 1-month postsurgical examination (complete glottic closure), and (C) 6-month postsurgical examination (incomplete glottic closure due to disease progression and initiation of systemic treatment).

using auditory feedback during voice production via bone and/or air conduction. However, the increased activity observed in the superior temporal gyrus may be artifact, perhaps reflecting auditory processing of scanner background noise by the subject.

At the time of the 6-month imaging session, quantitative voice parameters declined. Lesser volumes of activation were evident in the same network of regions shown in the previous imaging sessions. These changes coincided with the patient's disease progression and initiation of systemic therapy.

Data from the patient examined in the current study provide a preliminary characterization of the brain's ability to adapt to changes in voice production following surgery; however, there are clear limitations to the current study that underscore the need for further investigation in this realm. Firstly, the patient received systemic chemotherapy following the first postsurgical scan. Chemotherapy may affect fMRI results due, in part, to changes in cognitive function.<sup>26</sup> Previous studies have reported that 25–33% of individuals undergoing systemic chemotherapy show difficulty performing on standard tests of cognitive function. However, there is a limited amount of existing longitudinal data investigating changes in cognitive abilities before and after chemotherapy and how these changes might affect efficient voice production. Moreover, there is little available evidence revealing the causes of cognitive decline, including changes in the blood oxygenation-level dependent response measured during fMRI.

Detailed examination of the relationships between effects of rehabilitation, such as improved phonation and glottic efficiency, and changes in CNS activity, is necessary to increase our understanding of the central mechanisms involved in adaptation to voice disorders and rehabilitation. These findings have the potential for providing valuable information about alterations in sensorimotor representations following surgical restoration of glottic efficiency. However, replication and broadening of the scope of this investigation is necessary. This will permit a more detailed examination of chemotherapy-induced changes in neural activity. Furthermore, gaining a greater understanding of the central mechanisms of adaptation to voice disorders and rehabilitation will allow voice professionals to consider novel rehabilitation strategies for laryngeal and voice pathologies.

## REFERENCES

- Fattapposta F, Pierelli F, My F, et al. Psychophysiological approach in Parkinson's disease: L-dopa effects on preprogramming and control activity. *Neurol Sci.* 2002;2:S73-S74.
- Liotti M, Ramig LO, Vogel D, et al. Hypophonia in Parkinson's disease: neural correlates of voice treatment revealed by PET. *Neurology.* 2003;60(3):432-440.
- Abraham M, Bains M, Downey R, Korst R, Kraus DK. type I thyroplasty for acute unilateral vocal function paralysis following intrathoracic surgery. *Ann Otol Rhinol Laryngol.* 2002;111:667-679.
- Abraham MT, Mithat G, Kraus DH. Complications of type I thyroplasty and arytenoid adduction. *Laryngoscope.* 2001;111:1322-1329.
- Freidlander P, Aygene E, Kraus DH. Prevention of airway complications in thyroplasty patients requiring endotracheal intubation. *Ann Otol Rhinol Laryngol.* 1999;108:735-737.
- Kraus DH, Ali MK, Ginsberg RJ, Hughes CJ, et al. Vocal cord medialization for unilateral vocal cord paralysis due to intrathoracic malignancies. *J Thorac Cardiovasc Surg.* 1996;111:334-341.
- Kraus DH, Orlikoff RF, Risk SS, Rosenberg DB. Arytenoid adduction as an adjunct to type I thyroplasty for unilateral vocal fold paralysis. *Head Neck.* 1999;21:52-59.
- Dresel C, Haslinger B, Castrop F, Wohlschlaeger AM, Ceballos-Baumann AO. Silent event-related fMRI reveals deficient motor and enhanced somatosensory activation in orofacial dystonia. *Brain.* 2006;2006(129):36-46.
- Playford ED, Jenkins IH, Passingham RE, Frackowiak RS, Brooks DJ. Impaired activation of frontal areas during movement in Parkinson's disease: a PET study. *Adv Neurol.* 1993;60:506-510.
- Rascol OJ, Sabatini U, Chollet F, Montastruc JL, Marc-Vergnes JP, Rascol A. Impaired activity of the supplementary motor area in akinetic patients with Parkinson's disease. Improvement by the dopamine agonist apomorphine. *Adv Neurol.* 1993;1993(60):419-421.
- Ali SO, Thomassen M, Schulz G, et al. Alterations in CNS activity induced by botulinum toxin treatment in spasmodic dysphonia: an H<sub>2</sub><sup>15</sup> PET study. *J Speech Lang Hear Res.* 2006;49:1127-1146.
- Haslinger B, Erhard P, Dresel C, Castrop F, Roettinger M, Ceballos-Baumann AO. "Silent event-related" fMRI reveals reduced sensorimotor activation in laryngeal dystonia. *Neurology.* 2005;65:1562-1569.
- Birn RM, Bandettini PA, Cox RW, Shaker R. Event-related fMRI of tasks involving brief motion. *Hum Brain Mapp.* 1999;7(2):106-114.
- Ikeda A, Luders HO, Burgess RC, et al. Generator locations of movement-related potentials with tongue protrusions and vocalizations: subdural recording in human. *Electroencephalogr Clin Neurophysiol.* 1995;96(4):310-328.
- Wohlert AB. Event-related brain potentials preceding speech and non-speech oral movements of varying complexity. *J Speech Hear Res.* 1993;36(5):897-905.
- Wohlert AB, Larson CR. Cerebral averaged potentials preceding oral movement. *J Speech Hear Res.* 1991;34(6):1387-1396.
- Cox RW. AFNI: software for analysis and visualization of functional magnetic resonance imaging. *Comput Biomed Res.* 1996;29:162-173.
- Shipp T, Izdebski K, Reed C, Morrissey P. Intrinsic laryngeal muscle activity in a spastic dysphonia patient. *J Speech Hear Disord.* 1985;50(1):54-59.
- Rosen C, Lombard LE, Murry T. Acoustic, aerodynamic, and videostroboscopic features of bilateral vocal fold lesions. *Ann Otol Rhinol Laryngol.* 2000;109(9):823-828.
- Clower D, Hoffman JM, Votaw JR, Faber TL, Woods RP, Alexander GE. Role of posterior parietal cortex in the recalibration of visually guided reaching. *Nature.* 1996;383:618-621.
- Clower D, West R, Lynch J, Strick P. The inferior parietal lobule is the target of output from the superior colliculus, hippocampus, and cerebellum. *J Neurosci.* 2001;21(16):6283-6291.
- Kasdon D, Jacobson S. The thalamic afferents to the inferior parietal lobule in the rhesus monkey. *J Comp Neur.* 1978;177:685-706.
- McFarland N, Haber S. Convergent inputs from thalamic motor nuclei and frontal cortical areas to the dorsal striatum in the primate. *J Neurosci.* 2000;20(10):3798-3813.
- Nishitani Nobuyuki, Nagamine Takashi, Shibasaki Hiroshi. Modality-specific subregions in human inferior parietal lobule: a magnetoencephalographic study during cognitive tasks. *Neurosci Lett.* 1998;252(2):79-82.
- Fogassi L, Ferrari PF, Gesierich B, Rozzi S, Chersi F, Rizzolatti G. Parietal lobe: from action organization to intention understanding. *Science.* 2005;308(5722):662-667.
- Saykin AJ, Ahles TA, McDonald BC. Mechanisms of chemotherapy-induced cognitive disorders: neuropsychological, pathophysiological, and neuroimaging perspectives. *Semin Clin Neuropsychiatry.* 2003;8(4):201-216.